

**PennHIP Report**

Referring Veterinarian: Dr Daniel Smith Email: albertisvet@gmail.com	Clinic Name: Alhurtis Animal Hospital Clinic Address: 106 N Main St Alhurtis, PA 18011 Phone: (610) 967-7387 Fax: (610) 967-1582
---	--

**Patient Information**

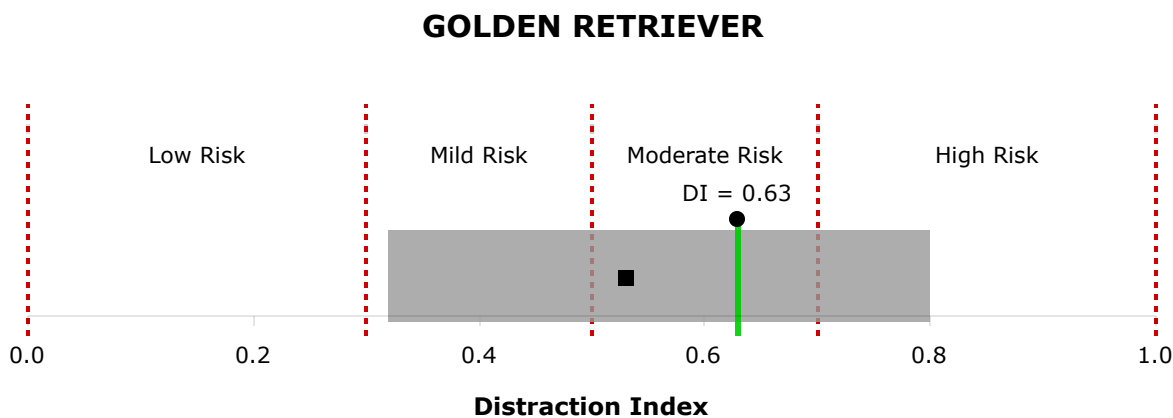
Client: SNYDER, SAMANTHA Patient Name: SPLASH Reg. Name: OPK'S RIVERSTONE'S CATCH WAVES NOT FEELINGS PennHIP Num: 160403 Species: Canine Date of Birth: 20 Jun 2019 Sex: Female Date of Study: 29 Jul 2021 Date of Report: 02 Aug 2021	Tattoo Num: Patient ID: 17515 Registration Num: SS13761103 Microchip Num: 985113003169301 Breed: GOLDEN RETRIEVER Age: 25 months Weight: 57 lbs/25.9 kgs Date Submitted: 29 Jul 2021
--	---

**Findings**

Distraction Index (DI): Right DI = 0.63, Left DI = 0.57.  
 Osteoarthritis (OA): **No radiographic evidence of OA for either hip.**  
 Cavitation/Other Findings: No cavitation present.

**Interpretation**

Distraction Index (DI): The laxity ranking is based on the hip with the greater laxity (larger DI). In this case the DI used is 0.63.  
 OA Risk Category: The DI is between 0.50 and 0.69. This patient is at moderate risk for hip OA.  
 Distraction Index Chart:



**BREED STATISTICS:** This interpretation is based on a cross-section of 22560 canine patients of the GOLDEN RETRIEVER breed in the AIS PennHIP database. The gray strip represents the central 90% range of DIs (0.32 - 0.80) for the breed. The breed average DI is 0.53 (solid square). The patient DI is the solid circle (0.63).

**SUMMARY:** The degree of laxity (DI = 0.63) falls within the central 90% range of DIs for the breed. This amount of hip laxity places the hip at a moderate risk to develop hip OA. **No radiographic evidence of OA for either hip.**